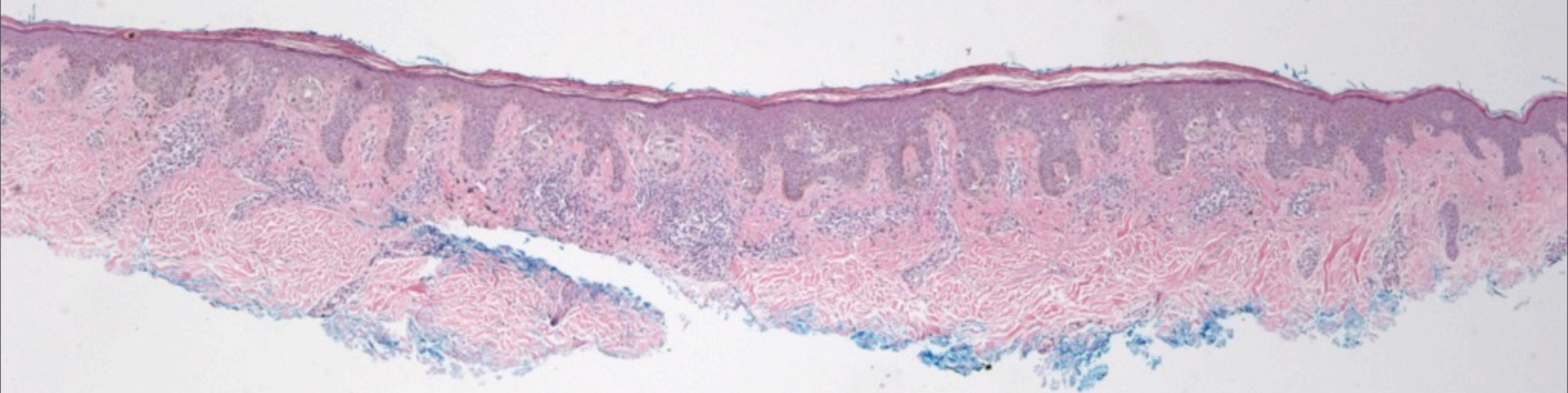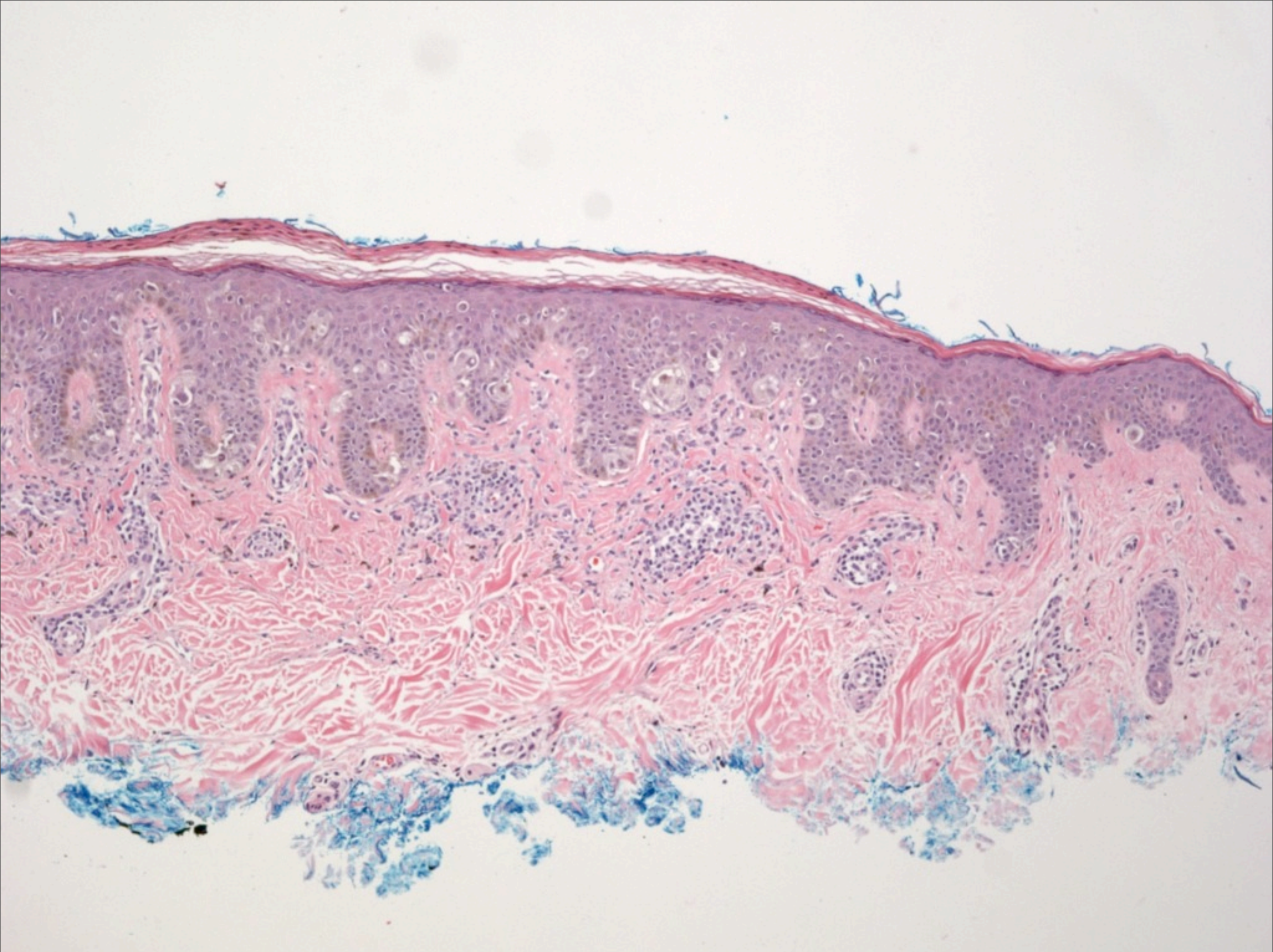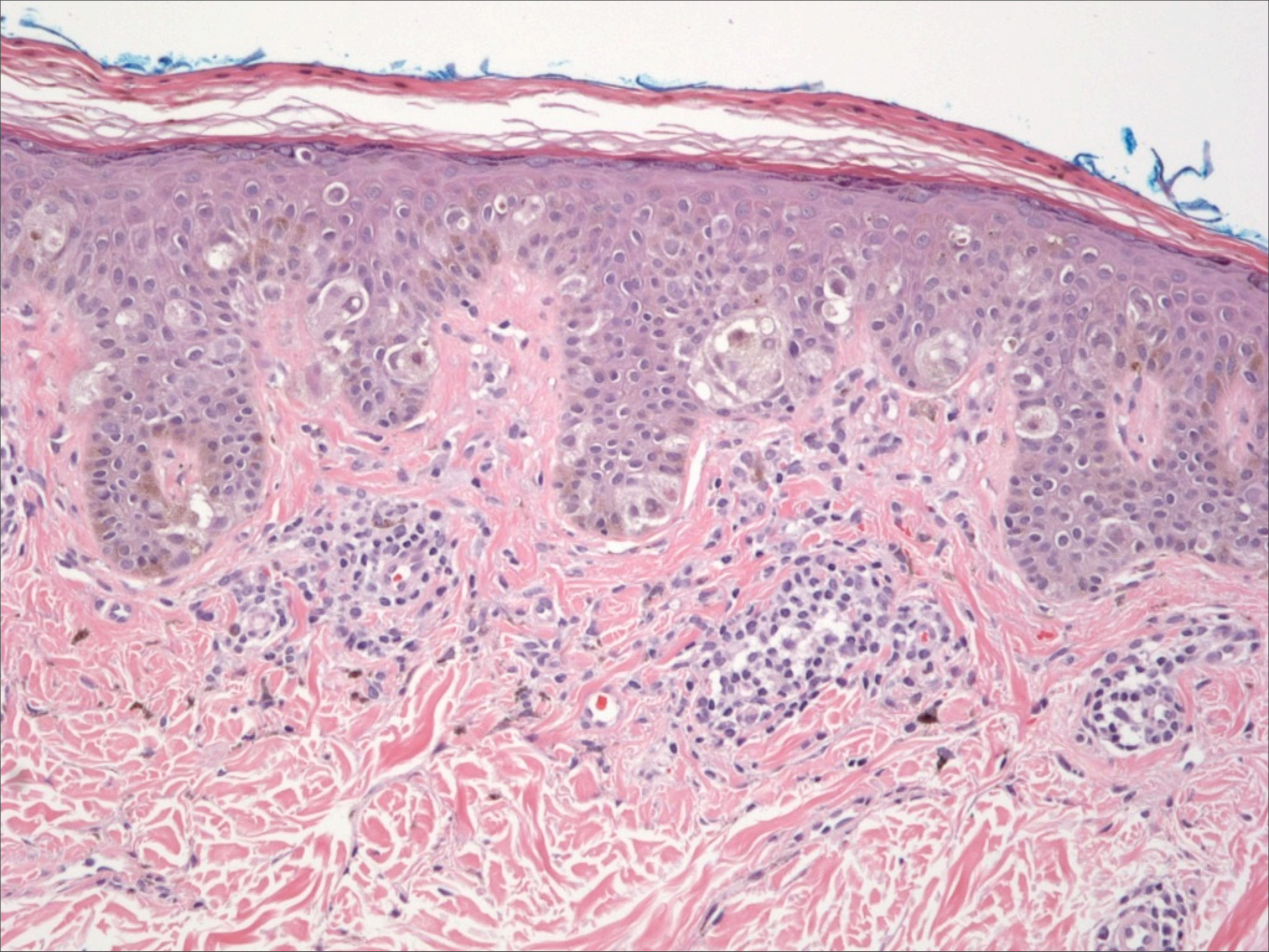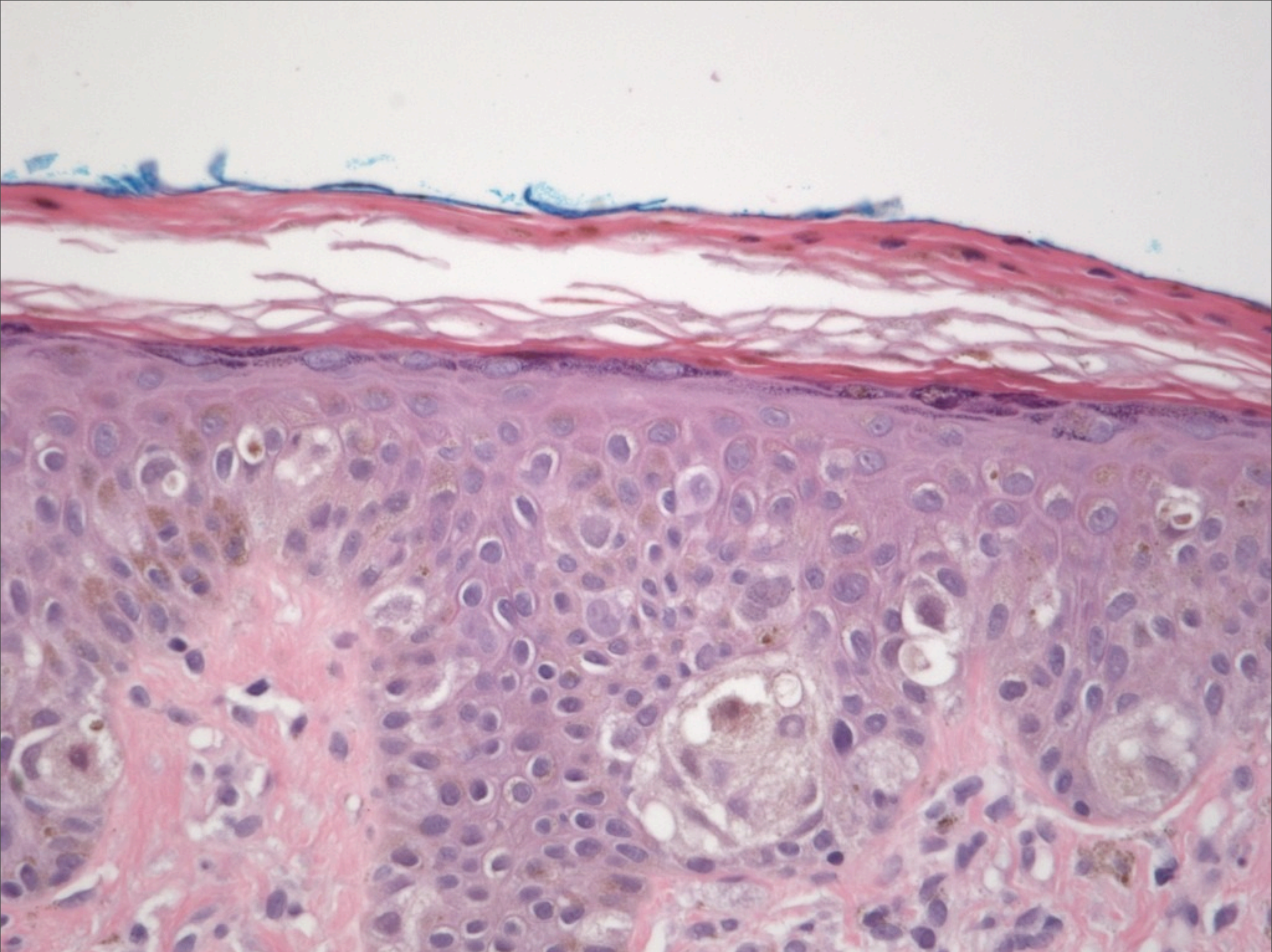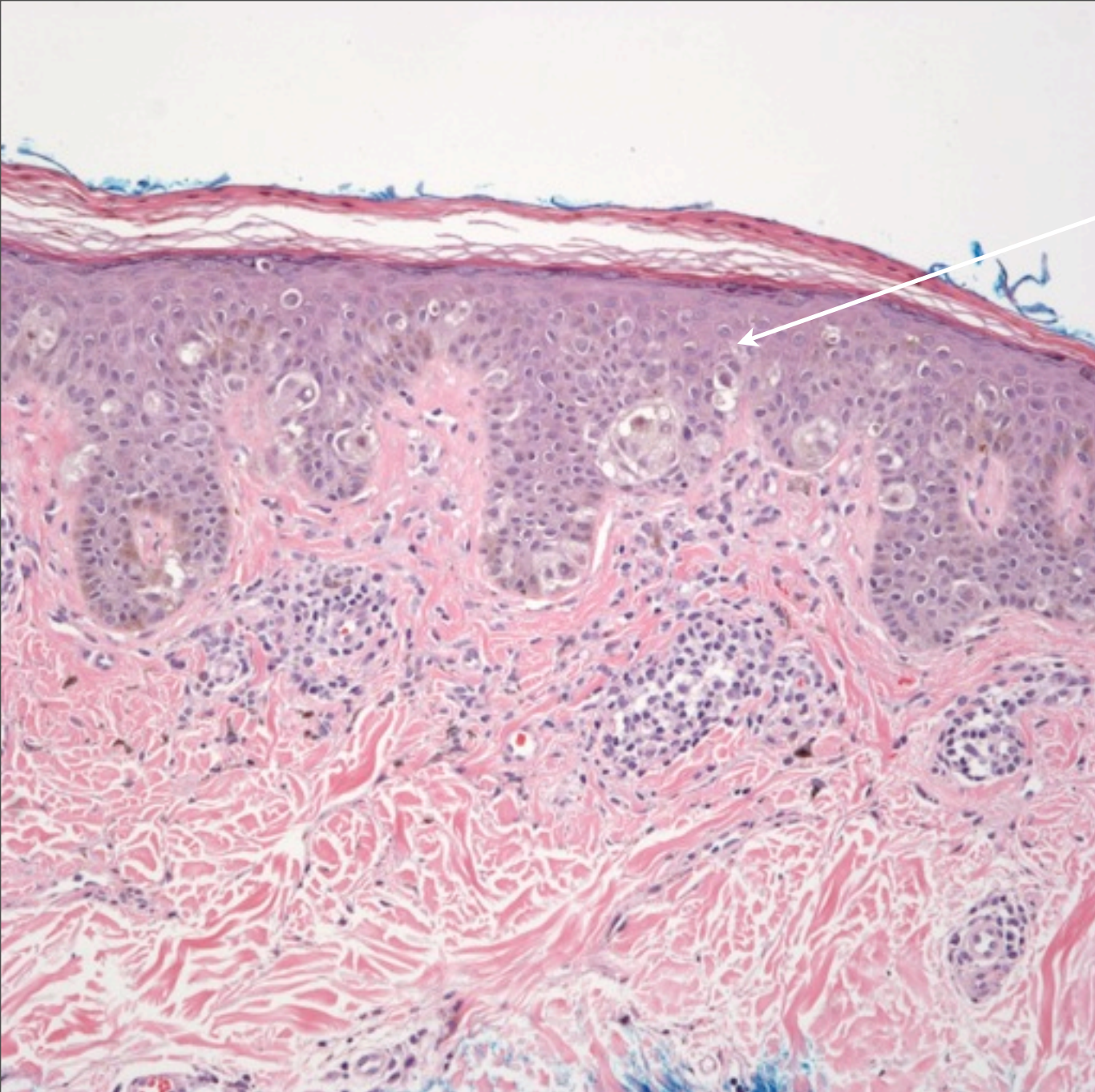


Malignant Melanoma in Situ, Superficial Spreading

Pleomorphic melanocytes
with intraepithelial scatter



May have discohesive expansile junctional nests